

BAD BEAKS

A PICTORIAL

Key Point: No matter how deformed or overgrown a beak appears, it almost never prevents a bird from eating.

Introduction

The beak includes the bones of the upper and lower jaws and their keratinized sheaths or rhamphotheca. This horny covering functionally replaces the lips and teeth. There is tremendous variation in the shape of the beak depending on how different species feed and live. In psittacines, the upper beak is massive and curved, whereas the lower beak is small and horse-shaped. This is why parrots are called hook bills. A parrot's beak is adapted to cracking large nuts and seeds as well as tearing and shredding wood from trees to provide nest sites. It is also used for grasping, climbing, preening, and displaying. It can be a formidable weapon yet also function as a delicate utensil for feeding newborn chicks.

Microscopically, the horny beak resembles skin, consisting of dermis and a modified epidermis. The epidermis is very thick and its cells contain free calcium phosphate and hydroxyapatite crystals, in addition to abundant keratin. This is what helps make the beak so hard. Keratin is an insoluble protein and is the principal constituent of the epidermis in hair, nails, and the beak.

The outer layers of the beak are continuously being replaced by normal wear and tear. Many bird owners erroneously believe that the upper beak grows from the cere and continues to the tip (or edges) where it is then worn off (likewise with the lower beak). On the contrary, beak tissue grows continuously outward (towards the surface) over much of the beak. As the keratinized epithelium reaches the surface, it is either worn off or may move distally a short distance before it is lost. Only towards the edges and tip does the beak tissue truly move rostrally.

The surface of the beak in juvenile parrots is smooth because the growth is new. However, as the bird reaches its first year and older, the beak takes on a more irregular appearance. This is a result of the normal wearing off of the outer keratin layers. Sometimes these layers flake off or peel, leaving behind ledges

on the beak's surface. These ledges are what make the beak look rough and scaly. These ledges can also be misinterpreted as cracks, which they are not. How irregular a bird's beak appears can also be related to diet. A diet low in vitamin A (seeds lack Vitamin A) can lead to hyperkeratosis, which clinically causes the beak to become thickened and overgrown. Such beaks can appear very scaly. The beak can also appear rough if the bird does not adequately rub it on hard inanimate objects, such as a lava stone or concrete and sand perches.

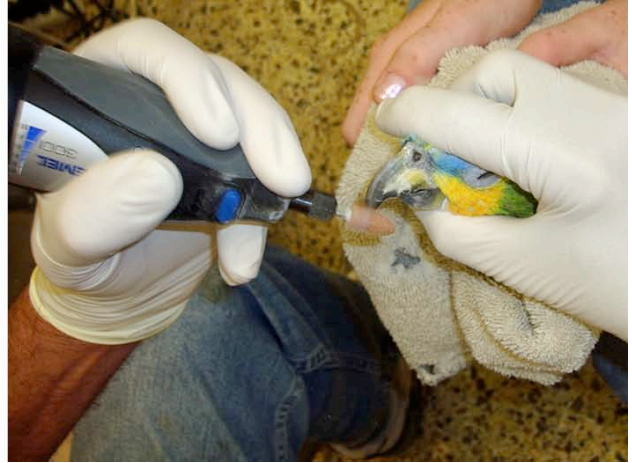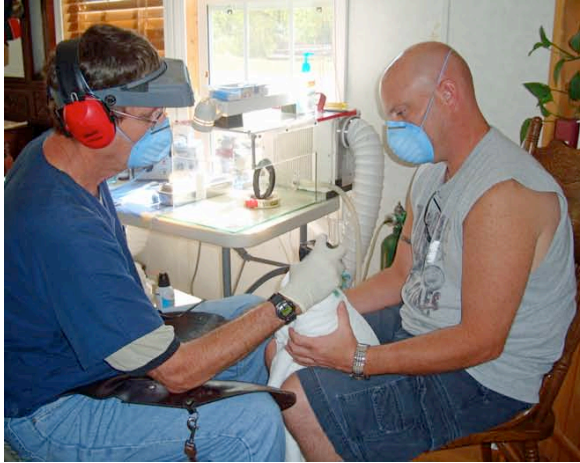Part of the physical examination of each bird includes an evaluation of the beak. Most healthy parrots have beaks in which the surface is slightly irregular and the tip a bit long. Such birds often receive a "cosmetic" beak trim. A cosmetic trim is not necessary for the health of the bird, but by doing so, the bird looks better, which in turn makes the client more appreciative.

Some birds have a pathologic condition which can change the normal outward appearance of the beak and affect some beak functions. In such cases "corrective" beak trimming is necessary. Aside from losing the entire upper or lower beak due to traumatic injury, overgrowth or deformity of the beak rarely affects a bird's ability to eat.

Beak trimming is accomplished using a variety of tools, including human nail trimmers, cuticle cutters, and a hobby tool (Dremel). The preferred dremel tool is electric and variable speed. A coarse conical grinding stone (#952) is the only bit this author uses no matter the size of the patient. Dremel tools and accessory stones are inexpensive (\$69 and \$3) and can be purchased at Wal-Mart, Home Depot, Lowe's, and most other hardware stores.

Anesthesia (isoflurane gas) is not required for beak trimming, but it sure makes it easier and less stressful, both for the veterinarian and his assistant, and for the bird. One should be aware that fully awake birds can stress easily during this procedure, especially when using a dremel tool, and deaths have been reported. Birds are usually held in a towel. One should also be very careful not to compress the bird too tightly which can adversely affect breathing and heart rate.

The following photographs show vivid examples of normal and abnormal beaks that were seen by the author.



Figs 1 and 2: Trimming a bird's beak during a routine examination. Face masks are worn to prevent inhalation of beak dust. The bird's body is held with a towel by an assistant. The vet secures the head with one hand and with the other, holds a dremel tool which is used to smooth out the beak surface and edges.



Figs 3 and 4: Blue-crowned conure showing a typical "cosmetic" beak trim. In the first picture, the beak surface appears a little rough and scaly and the tips are a bit long. After trimming the surface is smooth and the edges cleaned up and shortened. The beak appears shiny due to the application of mineral oil.



Fig 5: HYPERKERATOSIS Red-headed Amazon parrot. 25+ years old and fed a diet of seeds only. Hyperkeratosis due to low vitamin A has caused thickening of the upper beak. Notice the two beak layers towards the tip...the inner layer is the normal one. Yellow feathers on head are abnormal due to malnutrition.




Fig 6 and 7: Red-headed Amazon parrot with severe overgrowth of the upper beak, before and after trimming. Bird fed seed diet only. Bird was still able to eat. Notice that the lower beak is normal. Seeds are hulled using the front of the lower beak edge against the underside of the upper beak.



Fig 8 and 9: Examples of beak hyperkeratosis due to malnutrition related to Fatty Liver Disease in a Quaker parakeet and Blue and Gold macaw. Both birds were overweight. The macaw's beak has become necrotic.

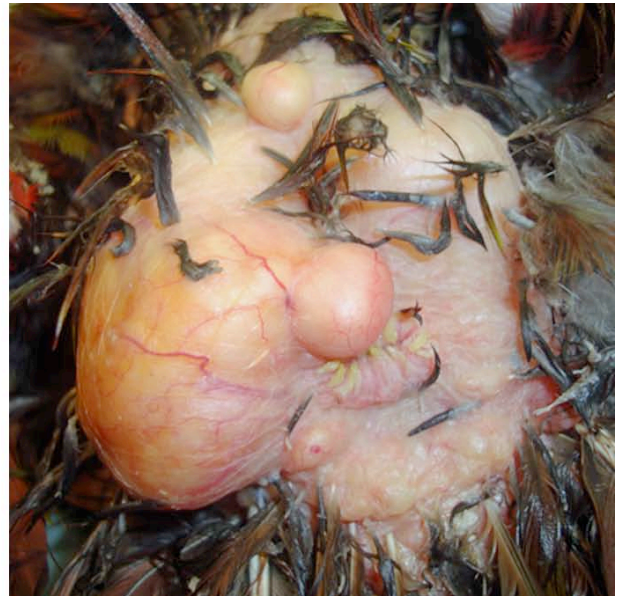

Fig 10 and 11: Severe beak hyperkeratosis with necrosis in a Severe macaw that was grossly overweight. Notice fatty tumors in abdominal region of this obese bird.



Fig 12 and 13: Two other examples of severe hyperkeratosis in a Blue-fronted Amazon and a Double Yellow-headed Amazon parrot. The Yellow-headed parrot also has keratinization on the underside of the tongue. This condition is known as Woody Tongue.

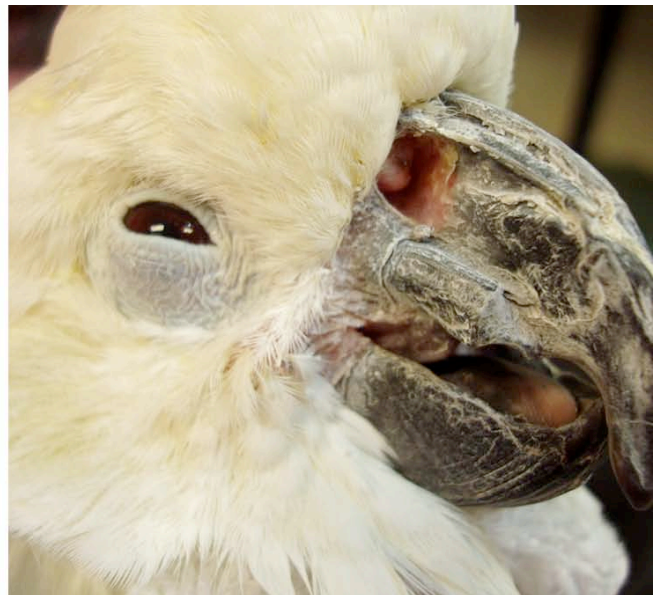
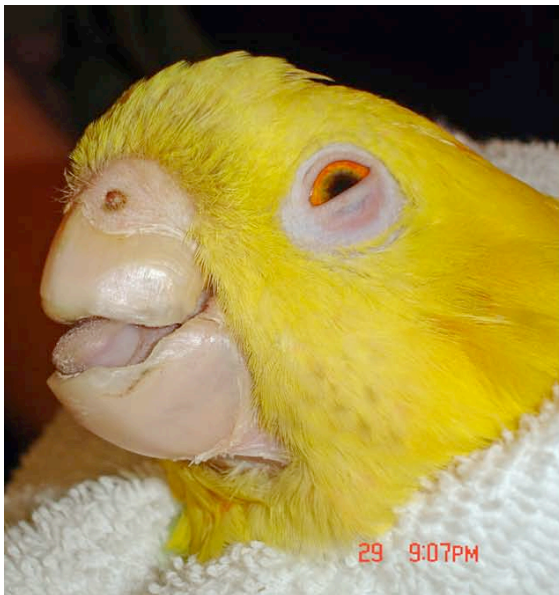
Fig 14 and 15: TRAUMA TO THE BEAK. Baby birds are prone to mutilation by their parents. If 1/3 of the beak or less is removed, the beak will grow back normally. If more than 1/3 of the beak is lost, it may look like this Amazon parrot. Mate aggression can occur in breeding pairs, especially Cockatoos. This female Umbrella cockatoo's beak was severely damaged by the male.

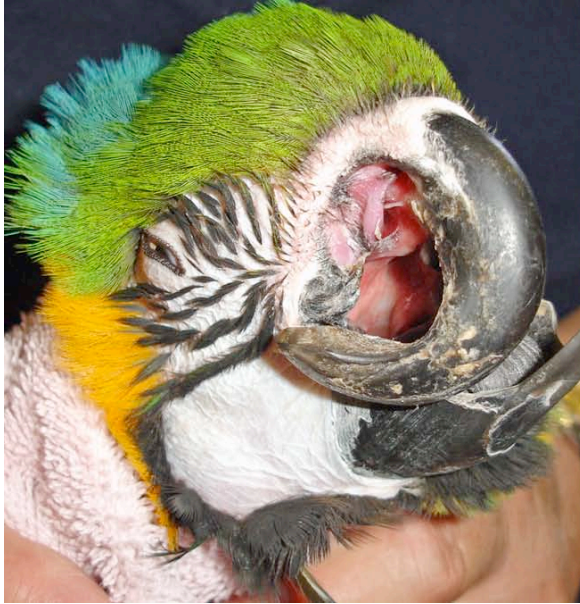

Fig 16 and 17: A mutilated Blue and Gold macaw (by parent birds when this bird was a baby) has resulted in a severely distorted scissor beak. The bird may look UGLY, but it eats fine...in fact she is fat! Healed, damaged upper beak and cere in a Mitred conure as a result of an encounter with another, larger bird.




Fig 18 and 19: Split lower beak (right on the midline) in a Blue-fronted Amazon. The two freely movable pieces cannot be reattached. Surprisingly this causes no problem with eating. A White-eyed conure with a split lower beak on the left side. Right lower beak section has elongated and risen to a level above the cere.

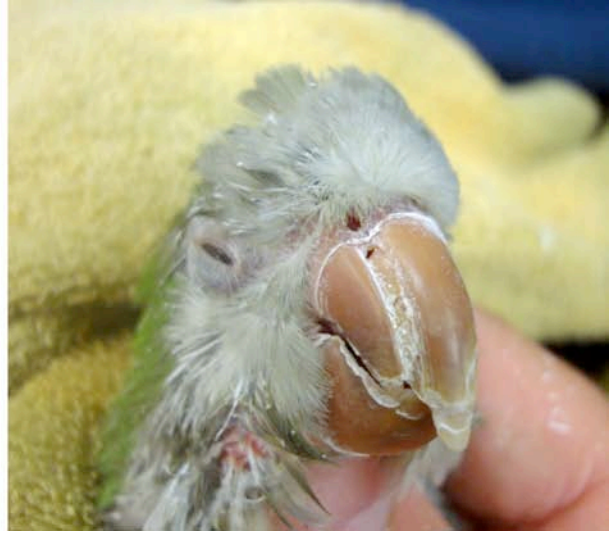

Fig 20 and 21: Green-cheeked conure who's upper beak was completely bitten off by a cockatoo. If this bird was a seed eater, it would probably not adapt to a pelleted diet in time to survive. Fortunately this bird was a pellet eater and has survived for more than 1 year. Quaker parakeet showing permanent scarring from a previous injury near the cere.

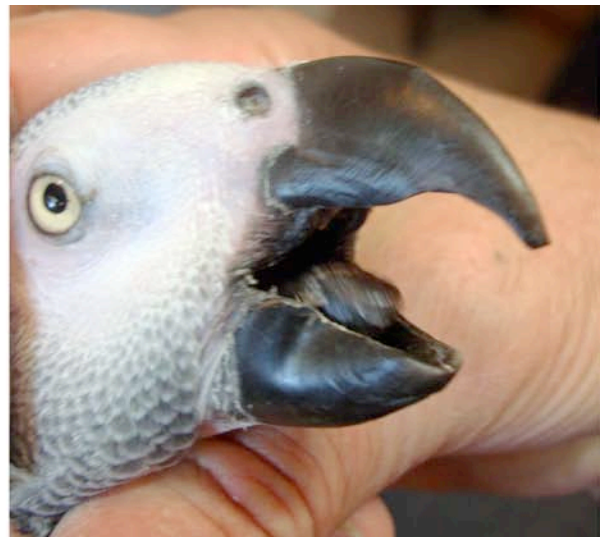
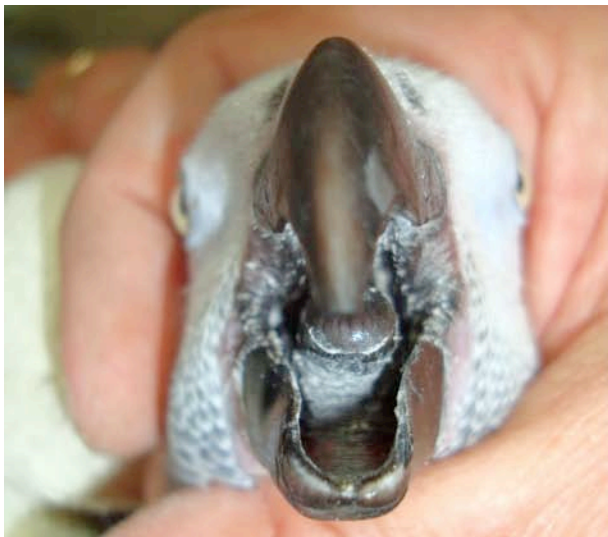
Fig 22 and 23 INDENTATION OF THE LOWER BEAK in African Greys. The cause of this condition which develops in some adult CAG's is unknown. The lower beak elongates, which in turn causes the upper beak to grow out to reach over the end of the lower beak. After trimming, the indentation is clearly visible.

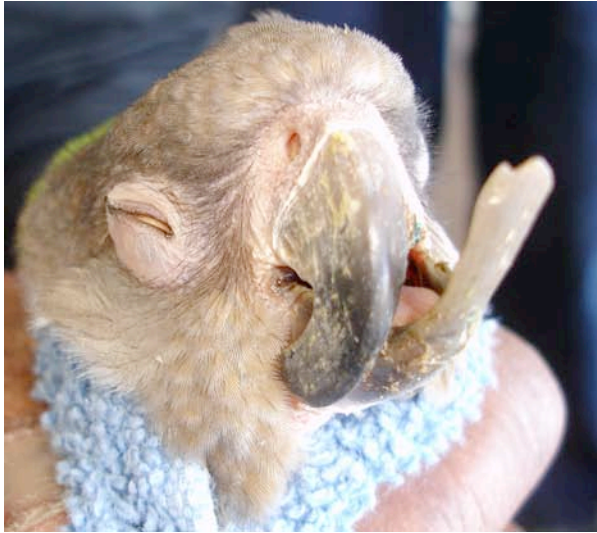

Fig 24 and 25: SCISSOR BEAK is a condition where the upper beak is bent to one side resulting in overgrowth of the lower beak on the other side. Causes may include heredity, incubation problems, malnutrition, infection, and trauma. Incorrect feeding techniques in baby birds have also been incriminated.

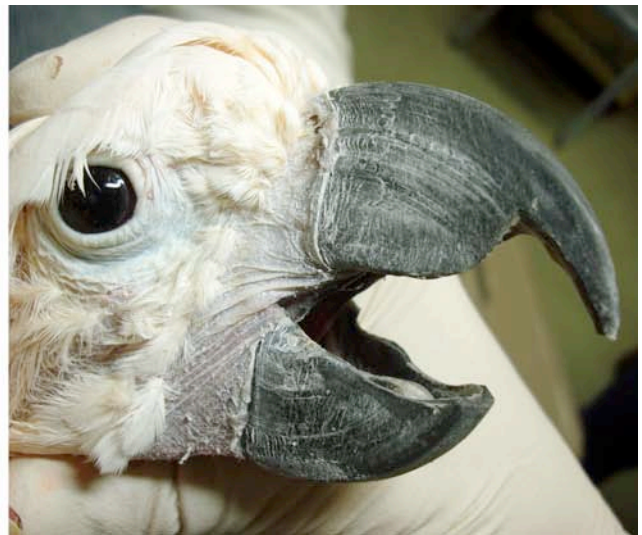
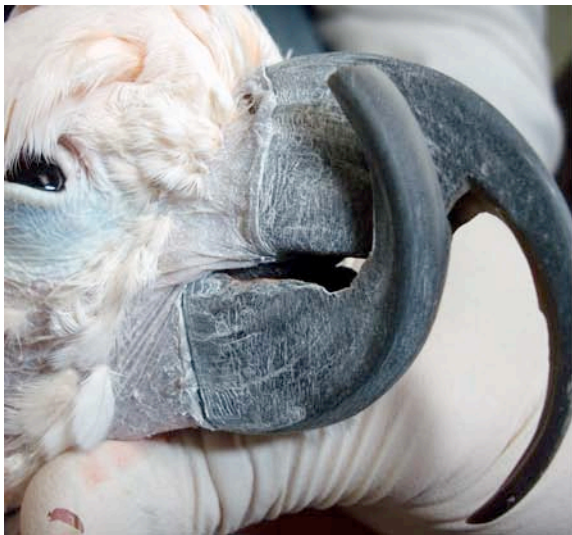
Fig 26 and 27: Severely overgrown scissor beak in a Moluccan cockatoo before and after trimming.

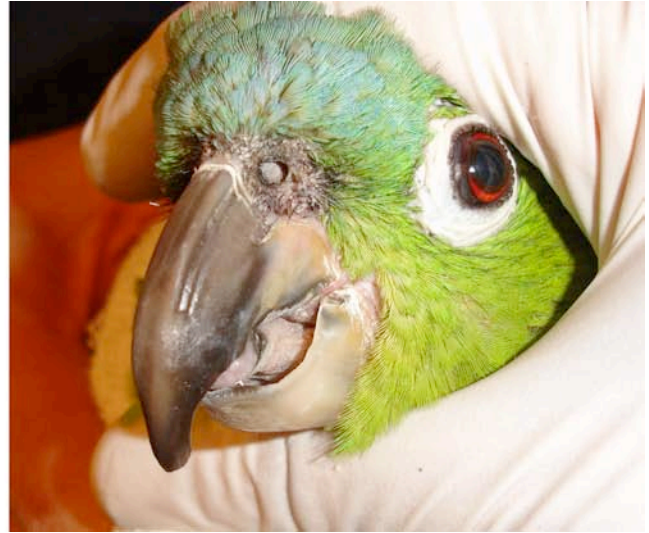


Fig 28 and 29: Very bad scissor beak in a Blue-crowned Amazon parrot before and after trimming. The tip of the lower beak was just touching the skin of the neck. This was a breeder bird...she was having no difficulty eating.

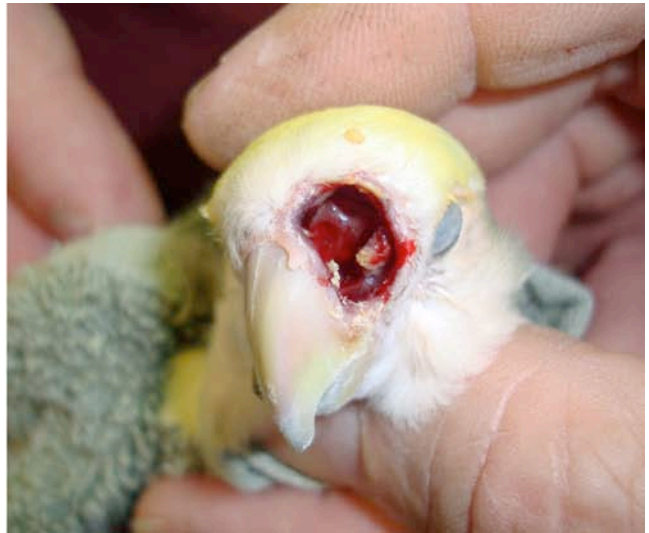
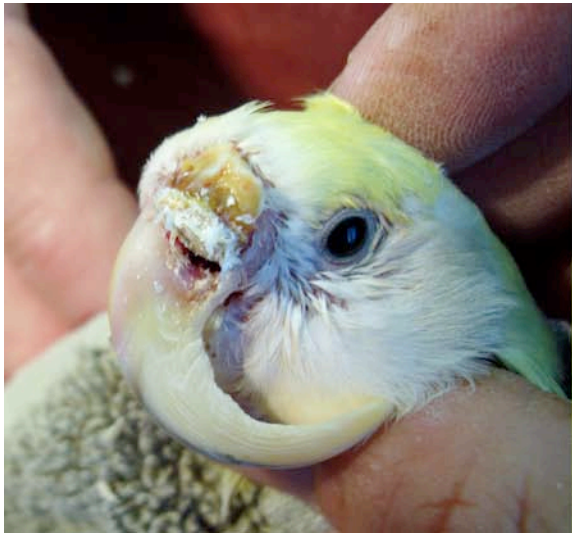
Fig 30 and 31: Grotesque scissor beak in a lovebird secondary to upper respiratory infection on the bird's left side. After the scab is removed, an eroded nasal and sinus cavity remains. Active infection is in remission.

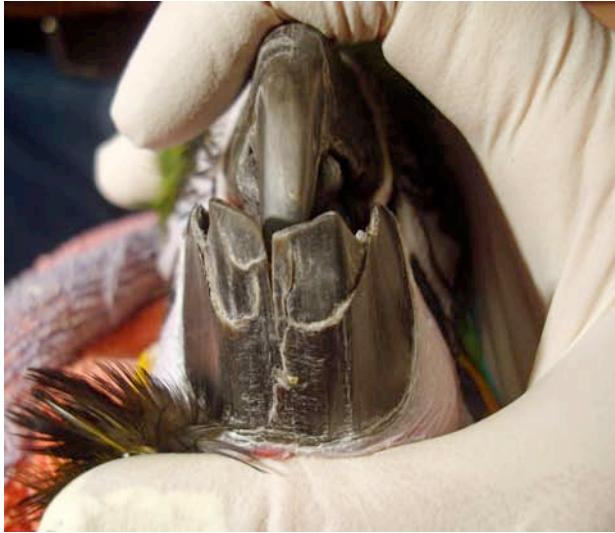

Fig 32 and 33: CRACKS in the front of the lower beak are not uncommon, especially in Mini-macaws and Jardines. They rarely extend more than $\frac{1}{2}$ inch downward and will never cause the lower beak to split in half. They can be mostly ground out with a dremel by shortening the front edge of the lower beak. Amazon parrot with a bizarre, chronic partially split lower beak.



Fig 34 and 35: INFECTION Beak rot secondary to Psittacine Beak and Feather Disease (Pbfd) virus in a severely affected Cockatoo. Bacterial infection (abscess) in the nasal cavity extending into the upper beak causing swelling and disease.



Fig 36 and 37: CANCER Squamous cell carcinoma involving the lower beak leading to overgrown of the upper beak. The end of the upper beak had punctured through the skin of the neck. This bird was euthanized. Small benign skin tumor occurring at the commissure of the beak that was easily removed.



Fig 38 and 39: MANDIBULAR PROGNATHISM. A congenital beak deformity occasionally seen in chicks, especially cockatoos, in which the upper beak grows downward, inside the lower beak. Corrective trimming, applying traction or tape splints to stretch out the upper beak, and dental acrylic prostheses are all treatment techniques that may be used. Corrective trimming shown here.

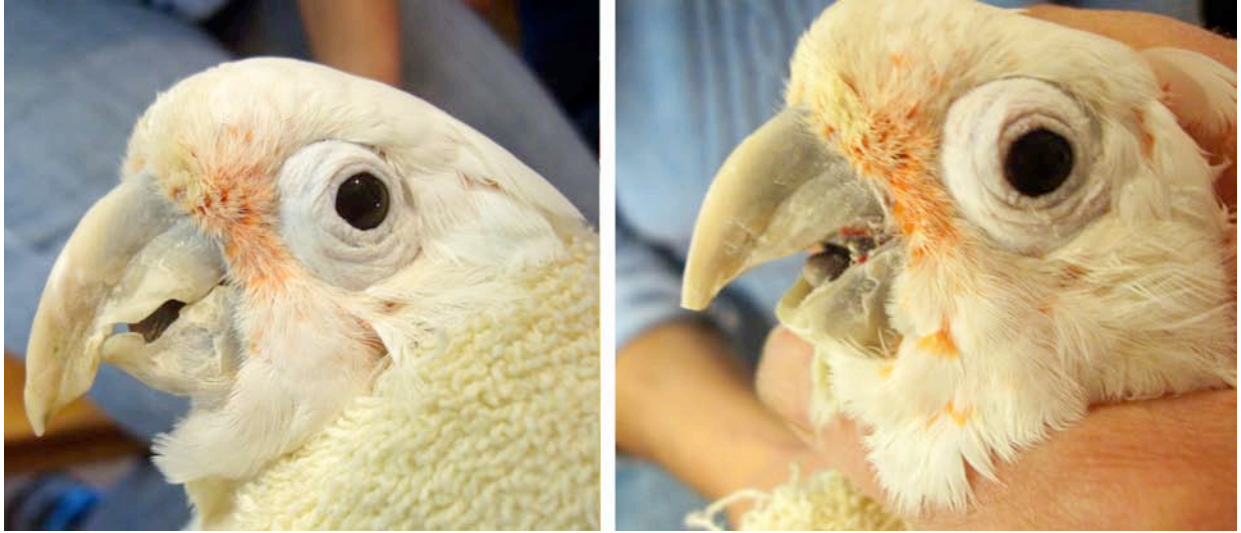

Fig 40 and 41: LOCKJAW This Goffin cockatoo has an arthritic beak condition which causes the bones of the jaws to become completely immobile when the beak edges come together. Food gets into the mouth only through the gape in the beak. Trimming 3x a year opens this gape and allows limited movement.



Fig 42 and 43: MISCELLANEOUS Harlequin macaw that was rescued showing severe elongation of the upper beak. Before and after pictures of a “corrective” trim.




Fig 44 and 45: Budgerigar infected with scaly-face mites. Note honey-combed encrustations around eye, on cere, and edge of beak. Beak involvement can cause severe deformity. Blue and Gold Macaw showing signs of allergy...pink, puffy cere with skin excoriation around nares and dried nasal discharge on beak.