

RECORDS

In 2008, I made the switch from a paper record keeping system to a computerized database.

I have an IBM laptop computer that I take with me on all my business trips. It is run by Windows XP and the database I am using is Microsoft Access.

I hired a computer database consultant to help construct and implement this database record keeping system which is streamlined for my specialized practice. A number of modifications were made in 2008 and 2009, but the final version is now in place.

Each new client must fill out a Client Information Form. This form includes client and bird information which is imputed into the database on their first visit.

Individual pet bird information includes bird type, name, band number, microchip number, implantation date, sex, tattoo, and age.

Every visit of each pet is recorded. It includes the visit date, reason for visit, whether isoflurane was given for the exam, weight, weight description, procedures performed, and any clinical findings. A diagnosis, any treatments, laboratory findings, and recommendations are recorded when appropriate.

Breeder birds, which are presented for surgical sexing only, have the following information recorded: bird type, sex, age, band number, and any comments. A permanent archive of all birds sexed is kept for each client.

If a client wants a copy of their pet's record, it can be printed at the clinic with an HP mobile printer which I bring with me. If the client wants a copy of the records at a later date, it can be e-mailed to them.

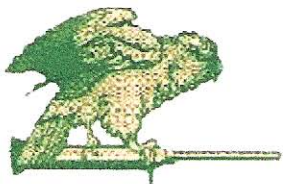
Each new client also receives a handout entitled Postoperative Home Instructions (Protocol #10). Business cards are always available.

This web site will also have information about my practice, articles pertaining to aviculture, health issues, and pet care, and client handout materials. This will be a work in progress over the next few years.



Picture: Updating a record on my laptop computer.

An example of a pet bird's record is included below. Also shown is a copy of a surgical sexing record sheet.



Scott E. McDonald, DVM
AVIAN LAPAROSCOPY
18 Waverly Avenue
Clarendon Hills, IL 60514

(630) 654-3580
Cell (630) 240-2751
DrSEMCD@aol.com

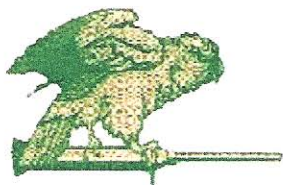
Name: Carapezza, Barb **E-Mail:** caraparrots@comcast.net
Address: 12827 Division **Bus Name:**
City/State: Blue Island, IL 60406 **Stop Code** IL

The birds listed below were surgically sexed on this date. The sex, estimated maturity, band, and any comments are noted. Male birds have been tattooed on the right wing-web, female birds on the left. Isoflurane anesthesia was used for this procedure. Induction was via a facemask at a conc of 5% with adequate oxygen flow. Once relaxed conc was reduced to between 2-3% for the duration. Anesthesia time: less than 8 minutes.

Surgical Sexing

Visit Date: 1/20/2009

Bird ID	Bird Type	Sex	Age	Band #	Comments
1	Capri Macaw	Female	2005	None	Wt: 1196 No pap M/V Nails (pap ck only)
2	Catalina Macaw	Male	Mature	None	Wt: 1096 Bald on the body Marble sized fatty tumors in SQ in abdomen just beneath chest on sides. No pap Rescoped...normal, healthy testes. Missing half of digit 3 L foot, nail on digit 2 L foot R eye may be blind
3	Scarlet Macaw	Female	Mature	None	Wt: 1060 Droopy L wing (carpal area) Marble sized fatty tumor SQ in abdomen just above vent...shouldn't affect breeding Bald on back Rescoped...ovary heathy and normal in appearance No pap M/V
4	Scarlet Macaw	Male	Mature	Removed	Wt: 1220 Band removed, too tight JAM 392 No pap M/V Stiff R wing Barbered on head/neck Rest of feathers OK Normal/healthy testes
5	Scarlet Macaw	Female	Mature	JAM 210	Wt: 1192 No pap M/V Rescoped...normal, healthy ovary Upper eyelid torn...old injury Nice looking bird, good feathering.



Scott E. McDonald, DVM
AVIAN LAPAROSCOPY
18 Waverly Avenue
Clarendon Hills, IL 60514

(630) 654-3580
Cell (630) 240-2751
DrSEMcd@aol.com

Name: Goodman, Karlene **E-Mail:** karg2@mac.com
Address: 832 Heritage Dr **Bus Name:**
City/State: Mt Prospect, IL 60056 **Stop Code** IL

Name of Bird: Simon **Tattoo:** No
Type of Bird: Green-Winged Macaw **Band Number:** None
Sex: Male **AVID:** 049 570 073
Age: 2002 **Implant Date:**

Isoflurane anesthesia was used for all procedures performed. Induction was via a facemask at a conc of 5% with adequate oxygen flow. Once relaxed conc was reduced to between 2-3% for the duration. Anesthesia time: less than 8 minutes.

<u>Visit Date</u>	<u>Reason for Visit:</u>	<u>Isoflurane</u>
Jan 12, 2009	Routine Grooming and Exam Anorexic 1 day	Yes
<u>Weight (g)</u>	<u>Weight Description</u>	<u>Procedures Performed:</u>
1,640	Fat	Beak trim, wing trim, nail trim

Clinical Findings:

Wt back up 140g in past year No pap. Good feathers Nothing else any different

Diagnosis / Treatment:

None

Laboratory / Recommendations:

On Roudybush low-fat pellets Repeat CBC/Panel... CBC: WBC 24,000. All other parameters on CBC and Panel are within normal range. Will monitor condition. Owner will call if bird doesn't start eating normally again